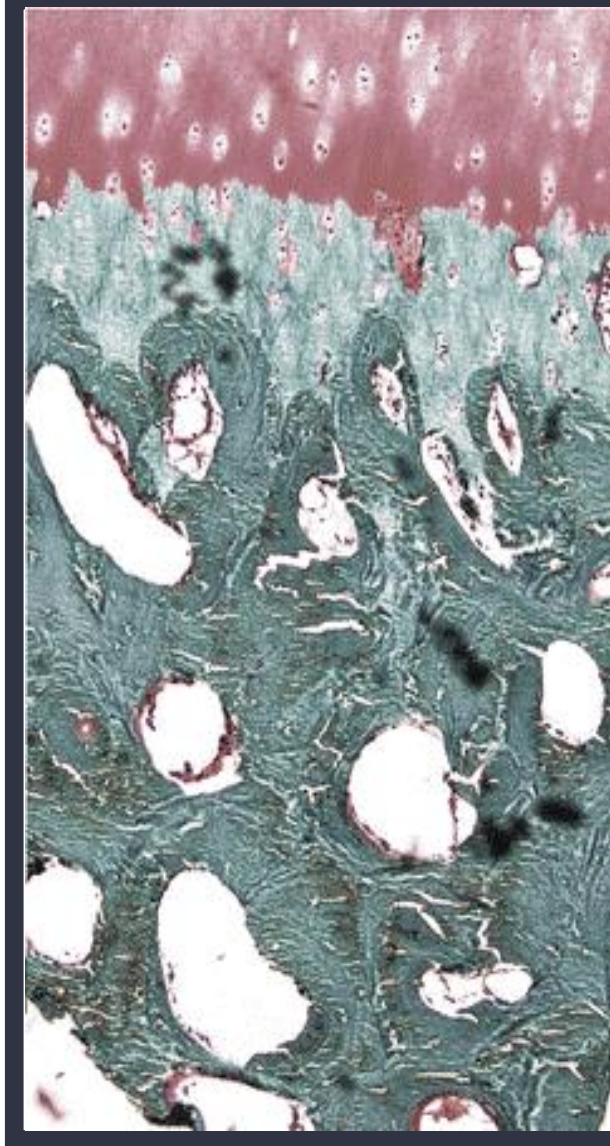


# SUBCHONDRAL INJECTION COMPLICATIONS

Christopher J. Williams, MD

## Current

- Bone Marrow Aspirate and / or Concentrate (1980's)
- Platelet Products (2014)
  - Platelet Rich Plasma
  - Platelet Lysate
- Bone Products (1970's)
  - Demineralized Bone Matrix
  - Calcium Phosphate / Carbonate / Sulfate
  - Bone Graft
  - BMP / Growth Factors



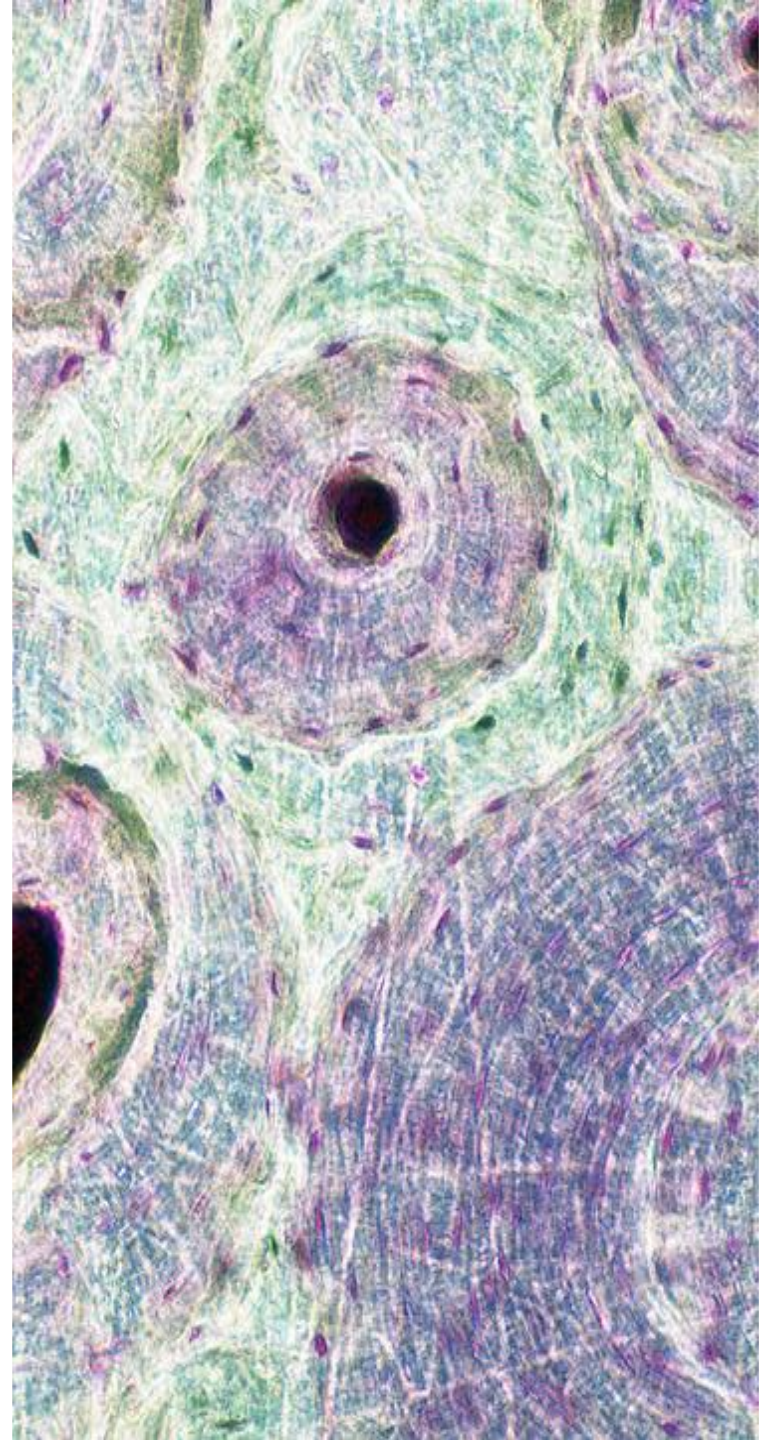
## Historical

- Corticosteroids (1970's)

# SUBCHONDRAL INJECTATES

- Published / Observed Complications

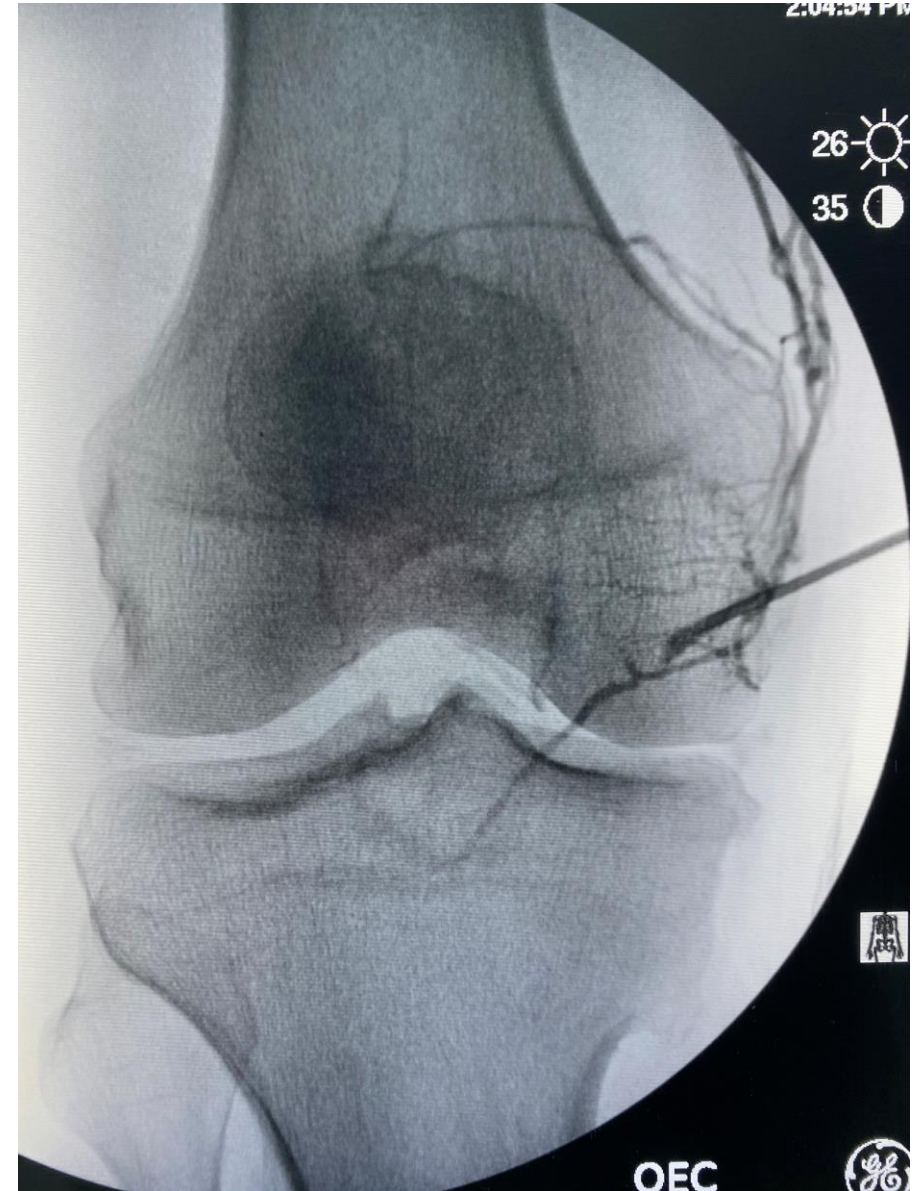
- Osteomyelitis
- Avascular Necrosis
- Subchondral Fracture
- Vascular Uptake
- Thrombus Formation
- Neurovascular Injury / Bleeding
- Cortical Breach
- Trocar breaking





## • Published / Observed Complications

- HPI: 50 year old male with Grade 3 medial compartment OA and meniscus degeneration
- Tx: Subchondral BMAC + PRP/PL
- Management: Attempted repositioning (depth and angle) without success. Aborted injection into the MFC. Completed injection into the MTP without issue.





Thank You!



Department of  
Rehabilitation Medicine